Pulpitis

Dr. Afrah Adnan Aldelaimi

B.D.S., C.D.I., M.Sc., Ph.D.
Oral & Maxillofacial Pathologist
University of Anbar - College of Dentistry

- Pulpitis is inflammation of the pulp of a tooth
- Acute pulpitis is the most frequent emergencies facing the dentist. Although pulpitis has a large number of possible causes, the primary one is dental caries.
- Bacteria can damage the pulp through toxins or directly after extension from caries or transportation via the vasculature.

- Because the pulp is contained within a solid chamber with a limited blood supply through the apical foramen and no collateral support, the inflammatory process that is so beneficial in the healing process in other parts of the body often becomes a mechanism of destruction in this confined location.
- it can produce sharp and prolonged pain because of the internal pressure and strangulation of the blood supply. Without intervention, an acute form of pulpitis rapidly progresses to pulpal necrosis.

- Mechanical sources of injury include traumatic accidents, iatrogenic damage from dental procedures, attrition, abrasion, and barometric changes.

- Severe thermal stimuli can be transmitted through large uninsulated metallic restorations or may occur from such dental procedures as cavity preparation, polishing, and exothermic chemical reactions of dental materials.
- Chemical-related damage can arise from erosion or from the inappropriate use of acidic dental materials.
- **Barotrauma (aero-dontalgia):** it is dental pain at high altitudes in unpressurized aircraft and in deep-sea diving due to formation of nitrogen bubbles in the pulp tissues or vessels.

Response of dentin and pulp to injurious stimuli

Dentin is a vital and cellular tissue so it has a major role in protecting the dental pulp from various injurious stimuli. The dentinal activity that helps to safeguard the pulp from noxious stimuli is as follows:

- Indirect pulpal response through dentinal changes: Dentinal sclerosis and Formation of reparative dentin
- Direct pulpal response: The pulpal tissue tries to eliminate or neutralize the damaging factors and initiate tissue repair.

Pathogenesis of pulpitis:

- Injured stimuli degranulated mast cells (inflammatory mediators such as histamine, bradykinin, neurokinins, neuropeptides, prostaglandins) are released causing vasodilation, increased blood inflow and edema that exist in a very confined area trying to eliminate any invading organisms, remove cellular debris, and limit tissue damage but it leads to increased pulpal injury or even death of the pulp by increase vascular pulpal pressures that compress venous return leading to pulp necrosis.

The decision to be made is one of the following:

- to restore the defective tooth structure conservatively, to remove the diseased pulpal tissue and to remove the entire tooth. In making the decision the clinician is really deciding whether the disease process taking place within the pulp is a reversible or an irreversible pulpitis.

Focal reversible pulpitis

- Focal reversible pulpitis or pulp hyperemia is a mild, transient, localized inflammatory reaction in the pulp, which can be treated by conservative means, without involving any form of direct pulp therapy. The tooth is sensitive to thermal changes, especially to cold.
- The pain is of very short duration and it disappears as soon as the thermal irritant is withdrawn. Pain also results when the tooth is exposed to extremely high temperatures.
- The affected tooth responds to stimulation by electric pulp tester at a lower level of current when compared with an adjacent normal tooth.
- Acute inflammatory reaction in the pulp limited to the odontoblastic or subodontoblastic regions, adjacent to the irritated dentinal tubules. Repair takes place by redifferentiation of odontoblast cells, which are damaged and sometimes with deposition of reparative dentin.
- Treatment: elimination of the primary irritating factors and restoration of tooth.

Acute pulpitis

It is an irreversible acute, intense inflammatory reaction in the pulpal tissue. The tooth is extremely sensitive to hot and cold stimuli; however the pain in acute pulpitis can start spontaneously in the absence of any stimulus. Pain persists for a longer duration even after the stimuli are removed.

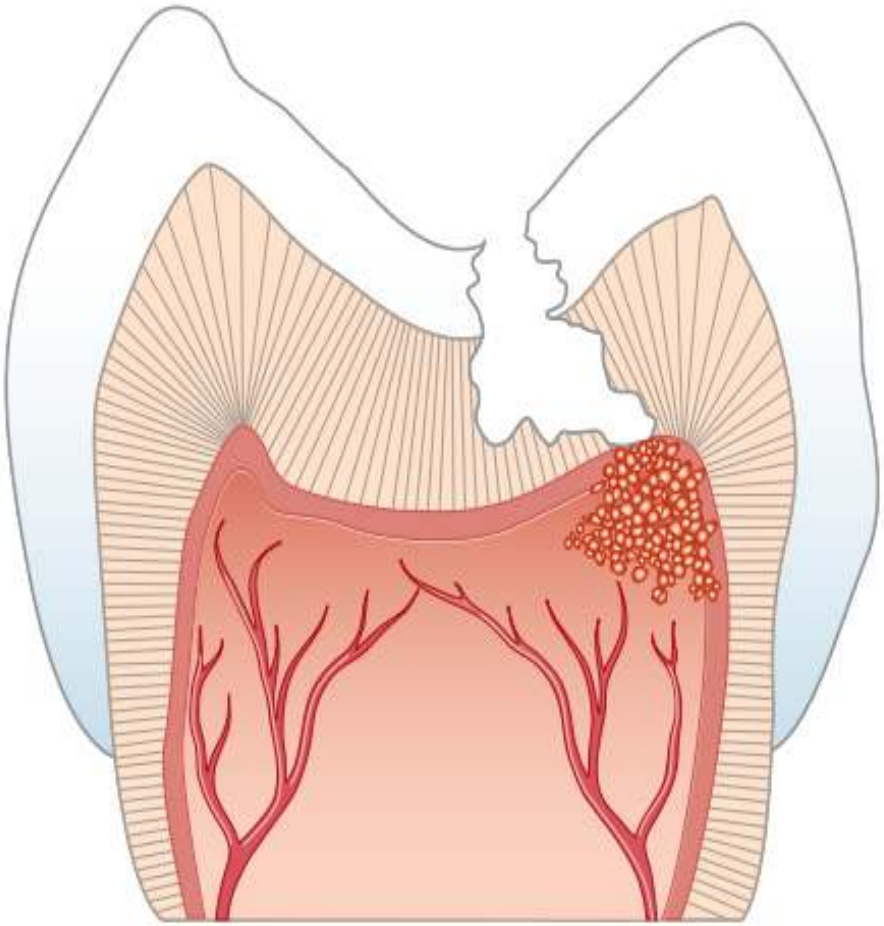

- In the initial stages of acute irreversible pulpitis the pain can be localized or rather the patient can identify the offending tooth, however in the more severe later stages the pain becomes regional and the patient is unable to identify the offending tooth.
- The intensity of pain increases during sleep because there is an increase in the local blood pressure in head and neck region in supine position, which results in increased flow of blood in the pulp chamber. More flow of blood in the pulp chamber causes more compression of the nerves resulting in more pain.
- Acute pulpitis is often associated with microabscess formation in the pulp along with liquefaction degeneration. When drainage is established, small amount of pus exudes from the opening, which has a noxious odor.

- The affected tooth responds to a lower level of current, if electric pulp tester is used.
- The tooth is neither mobile and nor tendered to percussion; unless the pulpal inflammation has spread beyond the root apex into the periapical region.

Acute pulpitis presents the following histopathological features: Severe edema in the pulp with vasodilatation. Micro-abscess formations, characterized by areas of liquefaction degeneration.

The treatment modalities are as follows:

- Drainage of exudate or pus from the pulp chamber.
- Direct pulp capping.
- Root canal treatment (RCT).

Chronic pulpitis

It is a condition characterized by a low grade, persistent inflammatory reaction in the pulpal tissue with little or no constitutional symptoms.

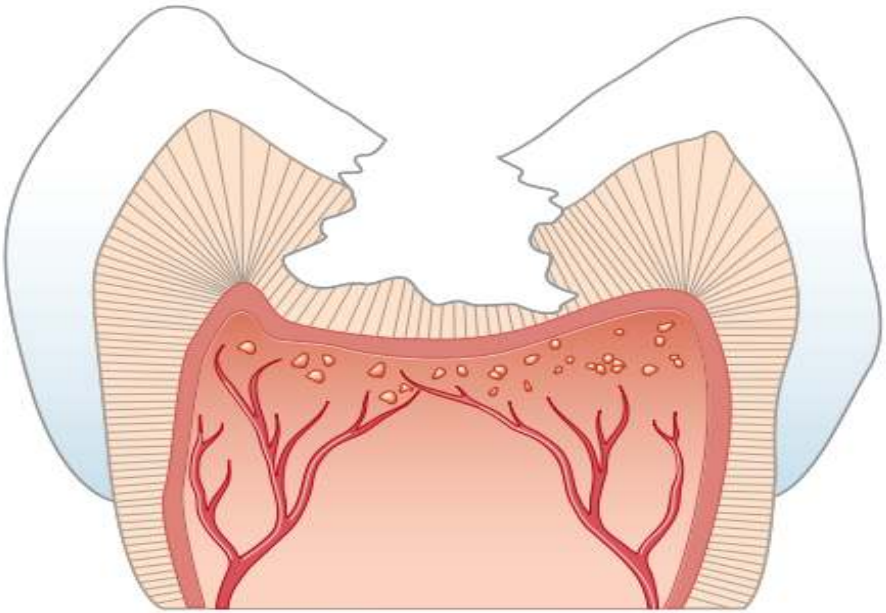

Etiology for chronic pulpitis is same as that of the acute pulpitis but here the irritants are of low virulence. The signs and symptoms in chronic pulpitis are much milder in comparison to the acute pulpitis as spontaneous attacks of an intermittent dull and throbbing pain or the tooth may be asymptomatic, the tooth usually responds to a higher level of current when electric pulp tester is used.

The chronic inflammatory response in the pulp is characterized by cellular infiltration by lymphocytes, plasma cell and macrophages, prolonged chronic inflammation may encourage fibroblastic activity in the pulp with formation of collagen bundles. Persisting chronic pulpitis may cause diffuse or solitary areas of calcification in the pulp. Chronic inflammation in the pulp in some cases may result in internal resorption of the tooth.

Treatment: Root canal treatment or extraction of tooth.

Chronic hyperplastic pulpitis:

- it is a cap of sub-acute inflamed granulation tissue that fills the entire space of the pulp chamber occur as a result from open tooth apex in children and young adults that produce hyperplastic granulation tissue that reduce the chance of pulpal necrosis secondary to inflammation and the tooth is asymptomatic except for feeling pressure in mastication.

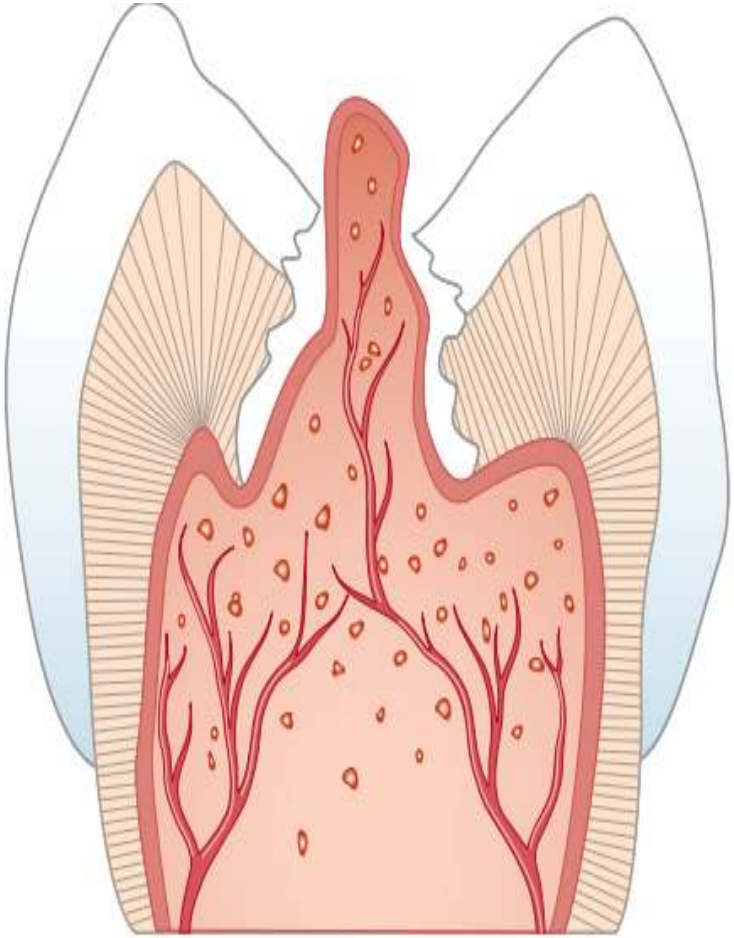

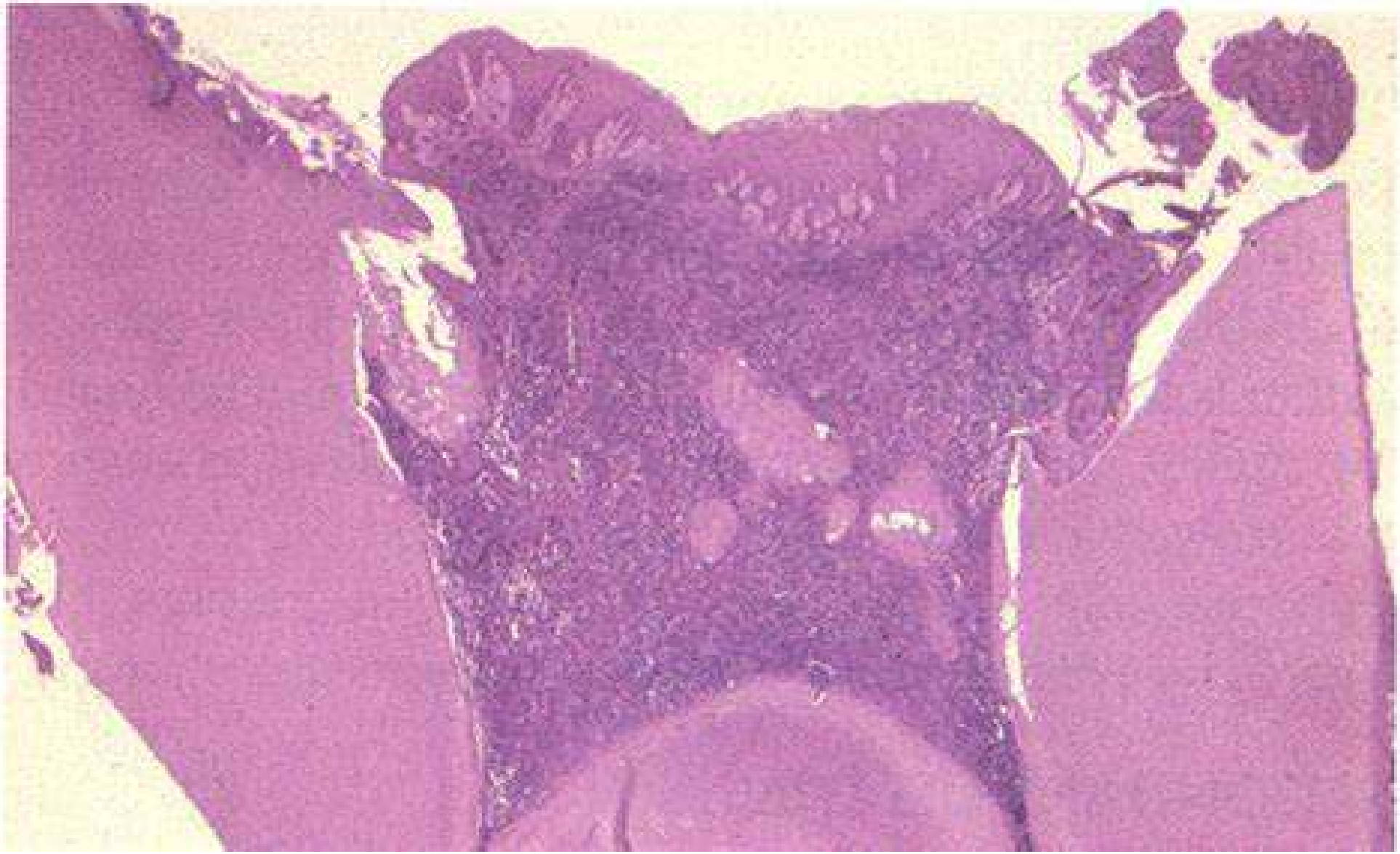

Pulp necrosis:

It occurs either due to pulpitis or due to injury or subsequent occlusion of the apical blood vessel.

A coagulative necrosis of the pulp occurs due to ischemia. The necrosed pulp may become secondarily infected by putrefactive bacteria from caries lead to liquifactive degeneration in the pulp.

The gangrenous necrosis of pulp is usually associated with a foul odor, when the pulp chamber is opened for endodontic therapy.

Diagnosis of pulpal diseases

History

- History of intense pain in the tooth, which continues even after the removal of stimulus, indicates an irreversible pulpal damage.
- If the pain or sensitivity comes down as soon as the stimulus is withdrawned, the condition is probably a reversible pulpitis.
- A dull pain preceded by sharp acute pain indicates either chronic pulpitis or pulp necrosis.

Clinical Examination

Clinical examination of tooth either visually or with hand instruments, ex; change in the color of the tooth can spell-out if the pulp is vital or not.

Radiographic Examination

Intraoral periapical radiographs or bitewing radiographs, etc. can help in establishing a diagnosis in pulpal disease. Although these findings are not always perfect, radiographs can often indicate if the carious infection has reached to the pulp or if the pulpal inflammation has already progressed beyond the apical foramen into the periapical tissue.

Clinical Test for Evaluation of Pulp Response (pulp vitality tests)

If the dental pulp is not in a healthy state it will generate abnormal responses to different stimuli
and this can help in making a diagnosis of the pulpal disease.

REVERSIBLE PULPITIS

- Inflammation of the pulp that is capable of a full recovery if the irritating factors subside or are removed. The symptoms reflect mildest forms of the inflammatory response, consisting of vasodilation with slight infiltrate of lymphocytes and disruption of the odontoblastic layer.

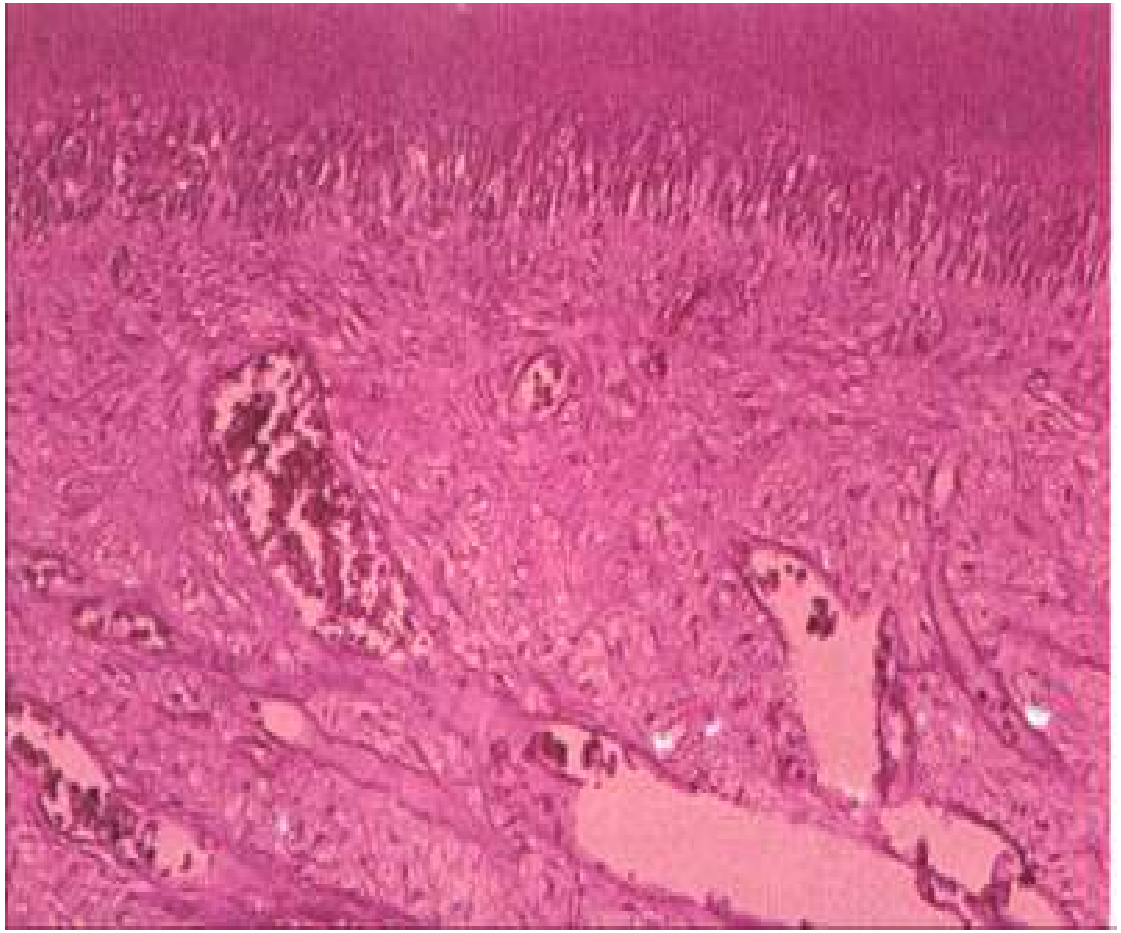

IRREVERSIBLE PULPITIS

- Pulp will not recover regardless of the attempts to treat it.
- Exo or endo treated.
- The pain less intense than reversible pulpitis. The pain from reversible pulpitis is easily localized to a particular tooth, the pain from an irreversible pulpitis may be referred to another nearby location, such as the lateral aspect of the face or to other teeth in the arch

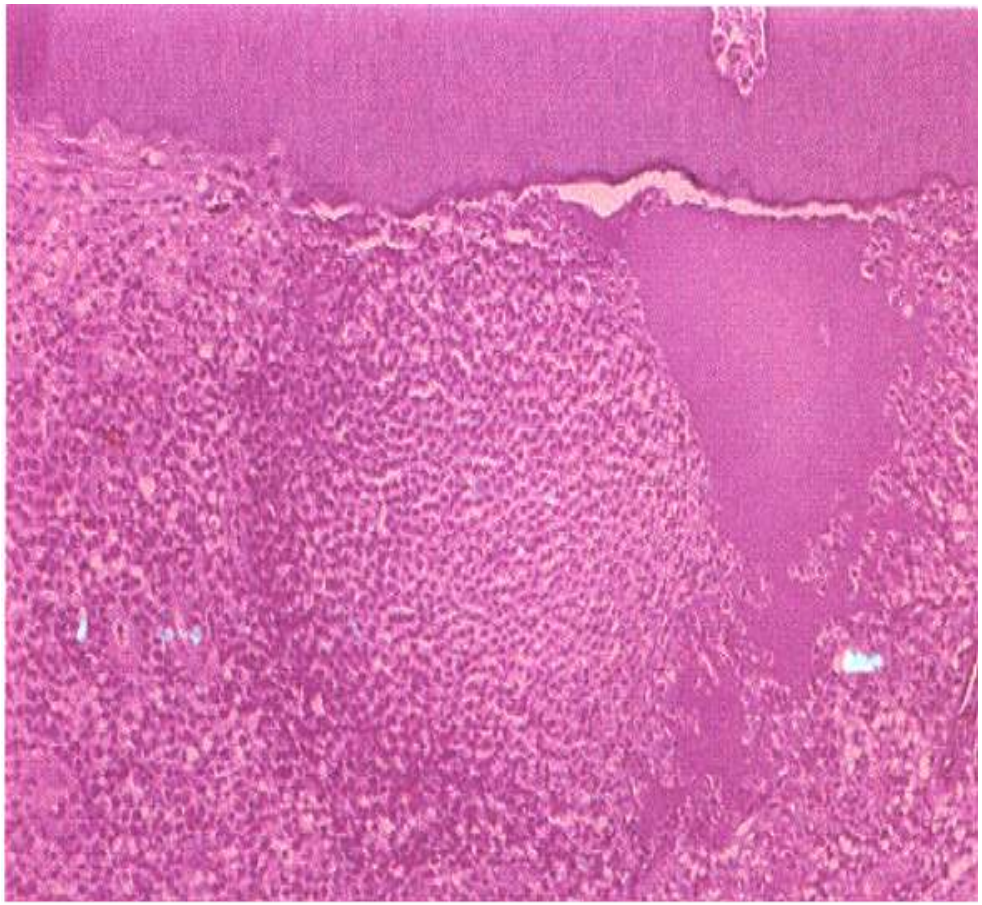

Pulpal calcifications:

- They are calcified bodies within an organic matrix and occur commonly in the radicular and coronal portions. It increase in prevalence with long-standing chronic pulpitis and with age and with a familial tendency. **True pulp stones** calcified material contain tubules and odontoblasts while **False pulp stones** are composed of concentric layers of calcified material with no tubular structure. The three types of pulpal calcifications are: Denticles, Pulp stones, Diffuse linear calcifications

Free True Denticle

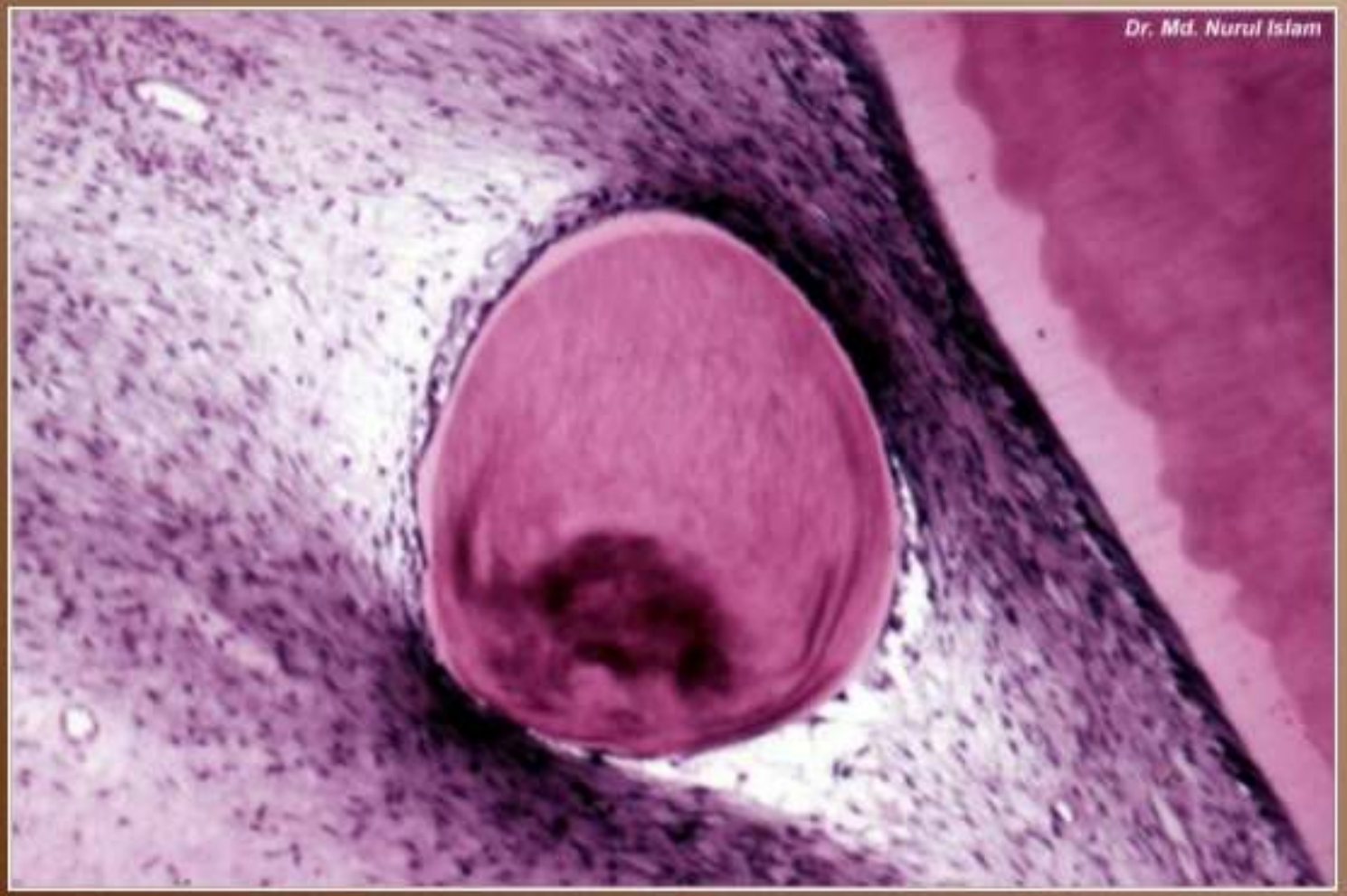

False pulp stone

A, False pulp stone; B, Pulp cavity

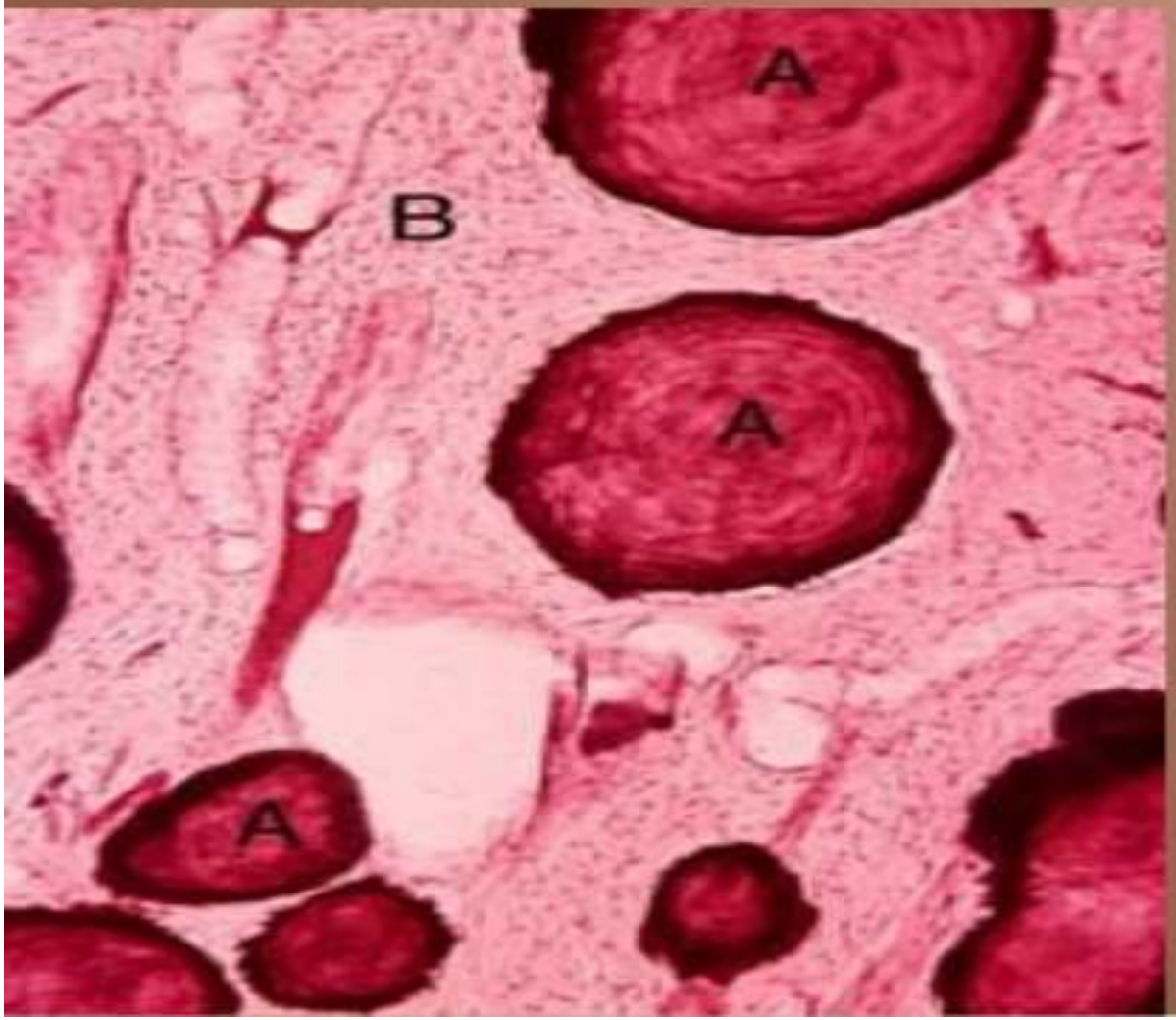

Denticles:

- they occur in the root canal and the pulp chamber adjacent to the furcation areas of multirooted teeth.
- they form during the period of root development by odontoblasts that deposit tubular dentin as they move away from the central epithelium therefor most denticles become attached to or embedded in the dentin.

3

Pulp stones:

- they are occured within the coronal portions of the pulp developed after tooth formation is completed and are usually free or attached. They develop around a central nidus of pulp tissue (e.g., collagen fibril, ground substance, necrotic cell remnants) extend outward.

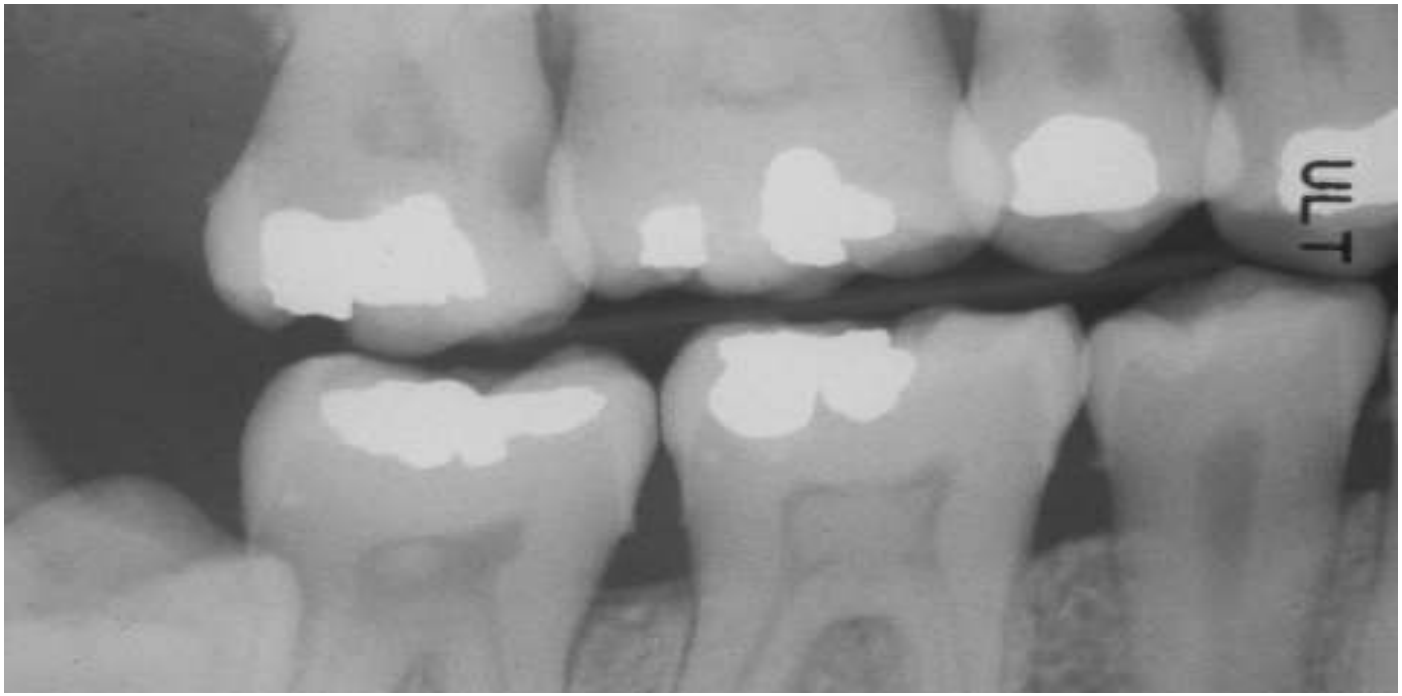

Diffuse linear calcifications:

- they are present in the pulp chamber or canals parallel the vasculature and the frequency increases with age.

Clinical significance of pulp calcifications:

- They interfere with root canal endodontic procedure
- They lead to periodontal destruc and tooth loss.
- **Treatment and prognosis:** no treatment is require and is not associat with any significant clinical alterations.

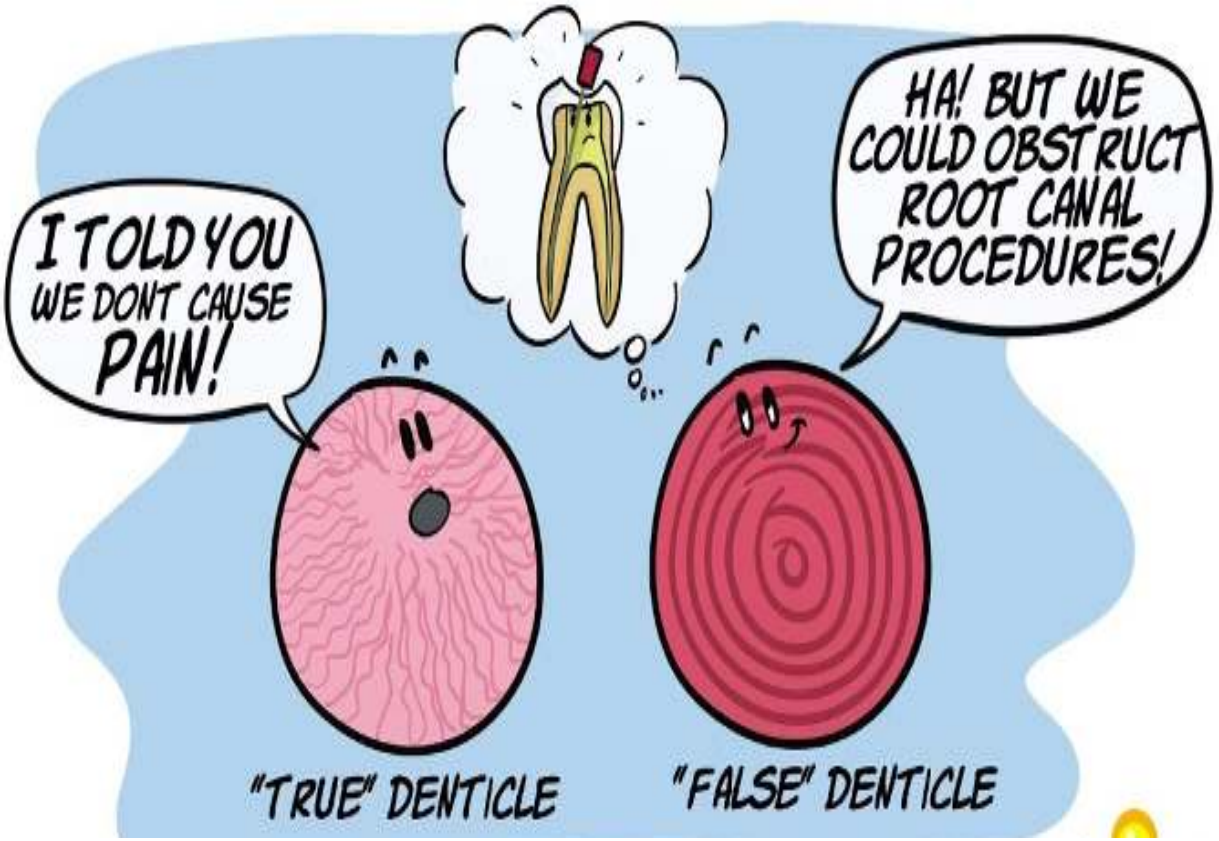

Age changes in teeth

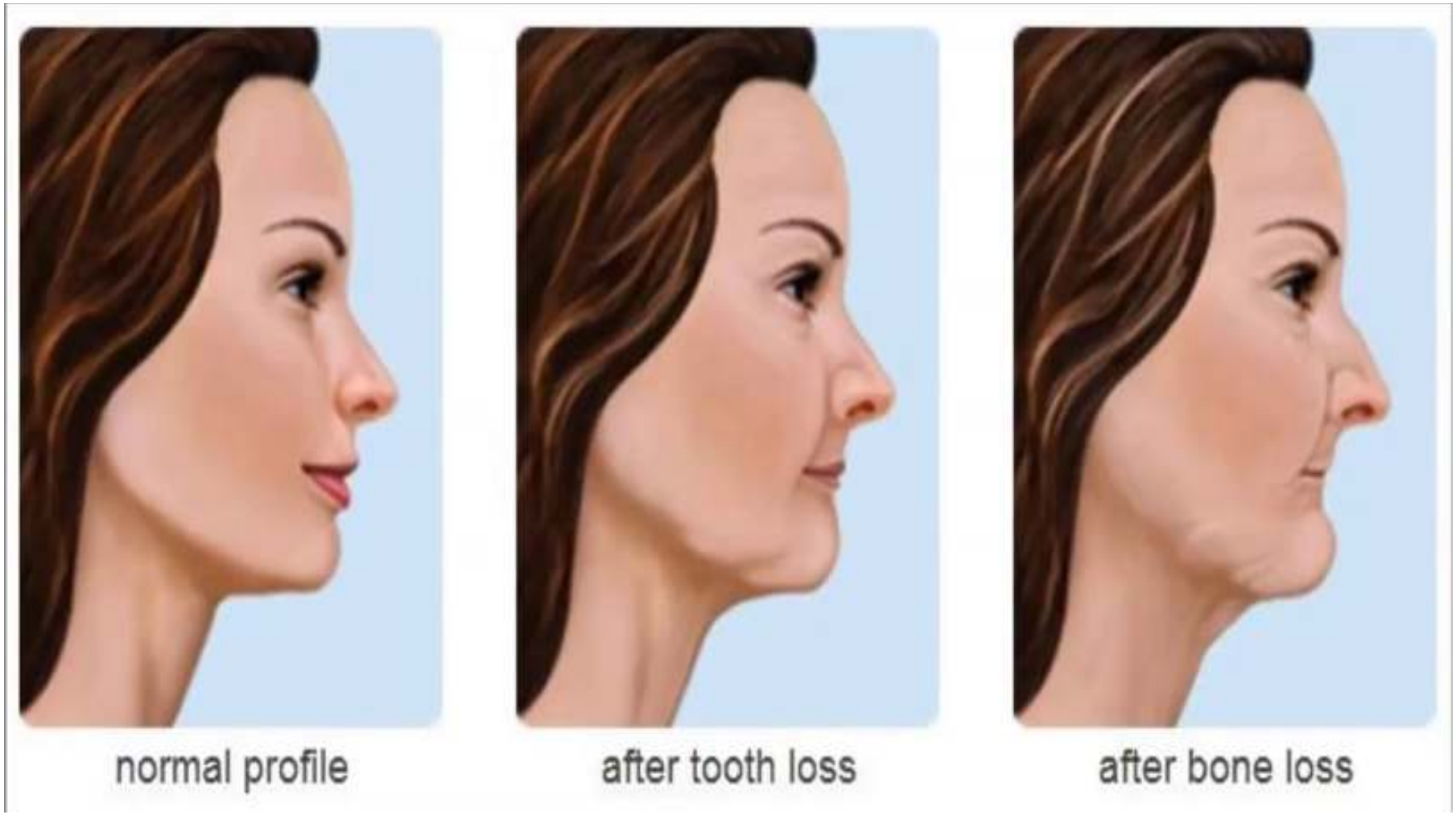
normal profile
after tooth loss
after bone loss

BONE LOSS AFTER TOOTH EXTRACTION

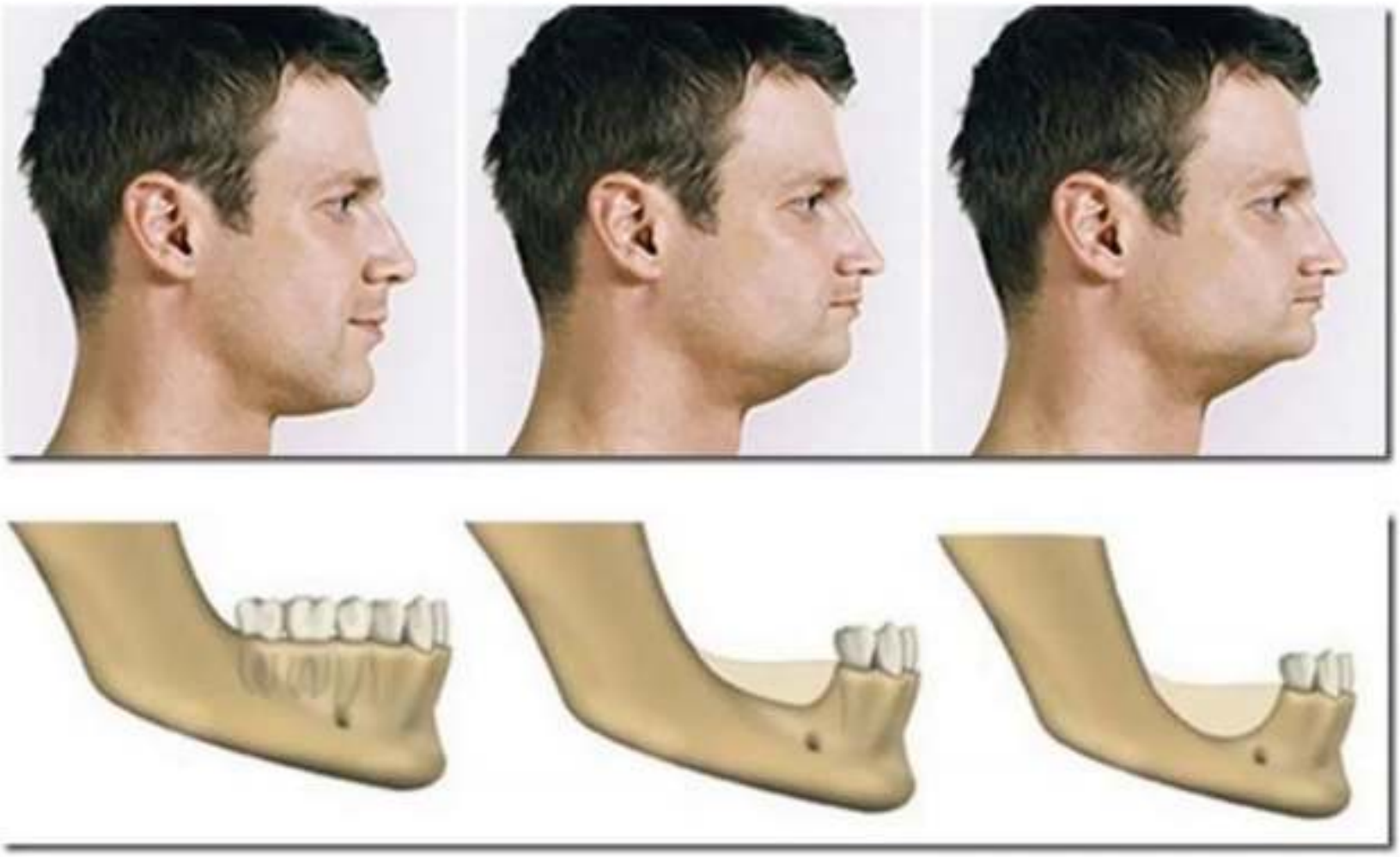

- **Pulp:** The volume of the pulp gradually decreases with age due to the continued production of secondary dentine, decrease in vascularity, cellularity with increase prevalence of pulp calcification. These changes may impair the response of tissue to injury and its healing potential.

- **Enamel:** it tends to become more brittle, less permeable and darker which may be due to absorption of organic material.

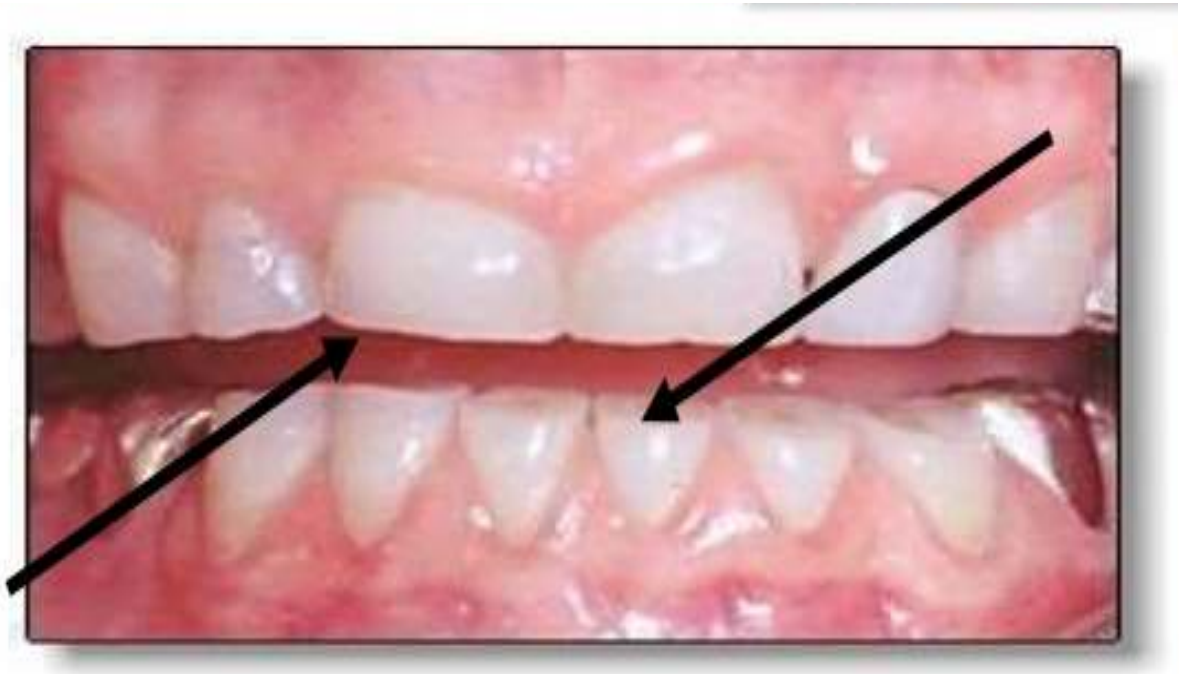

ENAMEL CHANGES

- Attrition
- Change in permeability
- Discoloration
- Chemical and surface changes

ATTRITION

- Physiological wear of occlusal or incisal and proximal surfaces of teeth resulting in a decrease in vertical dimension

- In severe attrition dentin may be exposed

Change in permeability

- Young enamel acts as a semi-permeable membrane and permits slow passage of water and molecular substances through the pores between the crystals.
- With age the enamel crystals grow in size and the pores between them is obliterated resulting in reduced permeability of the enamel.

DISCOLORATION

- Normal: white to yellowish white.
- With age darkening seen.
- Thought to be because of:

I. Loss of enamel rod
this loss alters the
reflection of enam
and results tooth c
change.

II. Deepening of dentin color seen through progressively thinning layer of enamel.

CHEMICAL AND SURFACE CHANGES

- Increase in fluoride and nitrogen content.
- Water and organic content decrease with age.
- Reduction in organic content reduces chance of caries in teeth with age.
- Loss of Perikymata

DENTIN

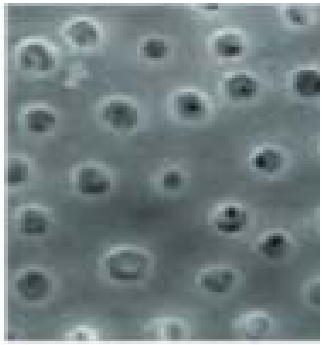

The main changes in dentin associated with aging are

- Increase in sclerotic dentin.
- Increase in the number of dead tracts.
- Increase in formation of reparative and reactive dentin.
- Vitality of dentin

Dentine:

- Formation of dentin proceeds throughout life. The **primary dentin** formed before completion of the crown by odontoblasts and followed by the formation of **secondary dentin** with ageing (increase after 35-40 years). Dentinal sclerosis leading to brittle roots and fracture during extraction, increase the susceptibility of caries and tooth wear.
- **Tertiary dentin** is irregular dentin formed in response to an ir ritant, such as caries, disease, or drilling to prepare a cavity for filling called also irregular dentin and reparative dentin .

DEAD TRACTS

- In normal dentin the odontoblastic processes may disintegrate and the empty tubules get filled with air. These are called dead tracts.
- They appear black in transmitted light and white in reflected light.

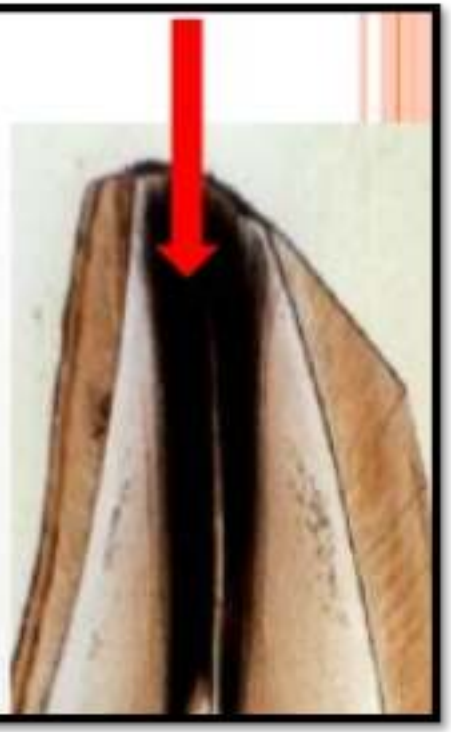

- If the provoking stimulus cause destruction of the original odontoblasts, the new, less tubular dentin formed by newly differentiated odontoblast like cells is called Reparative dentin.
- However if the odontoblast survive the provoking stimuli the dentin produced by them is called Reactionary dentin

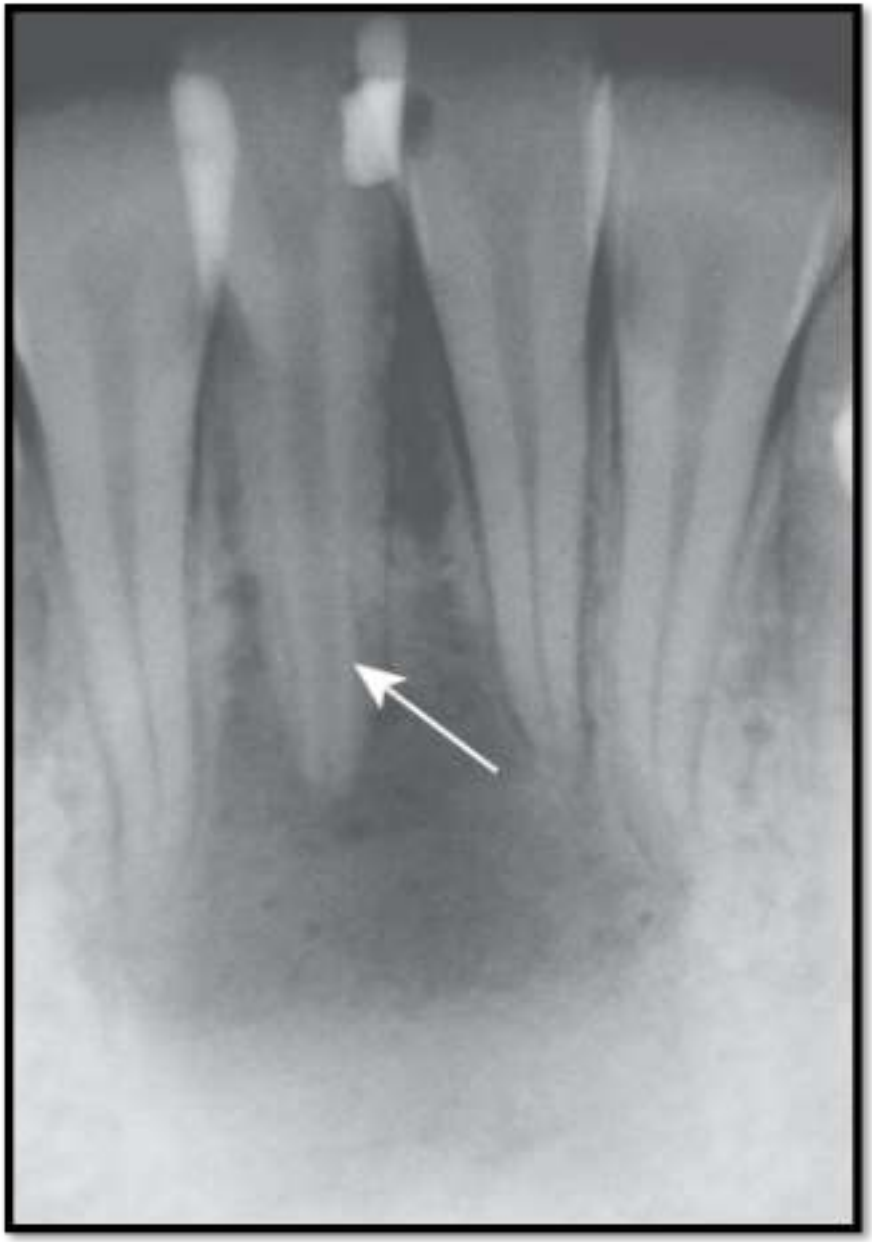

Cementum:

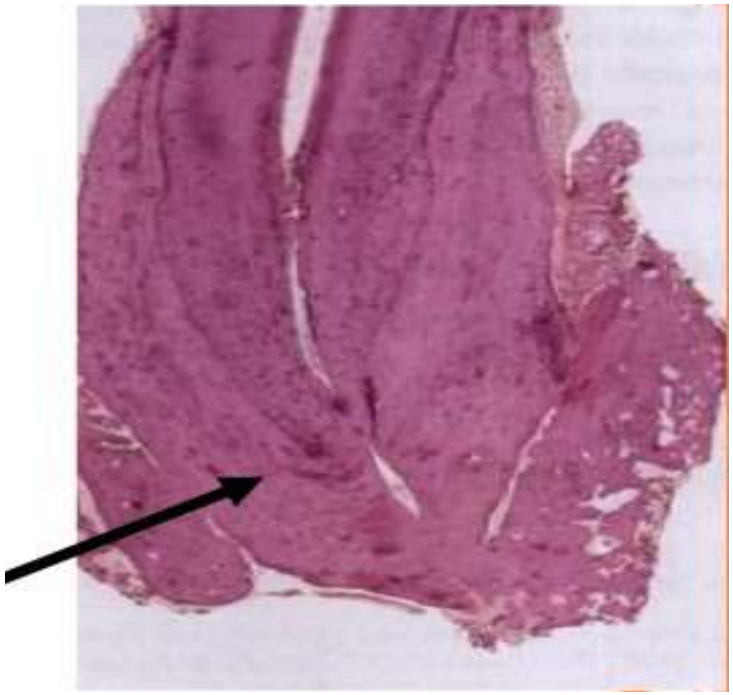

- continues formation throughout the life especially in the apical half of the root to compensate for interproximal and occlussal attrition.

HYPERCEMENTOSIS

- It is an abnormal thickening of the cementum.
- may be generalized or localized ,diffused or limited.

CEMENTICLES

- They are ovoid or round calcified structure that are formed as a result of calcification of the degenerated periodontal tissue or the epithelial rests of Malssez.
- Cementicles may be:

1. Free in the periodontal ligament.
2. Attached the cementum
3. Embedded in the cementum

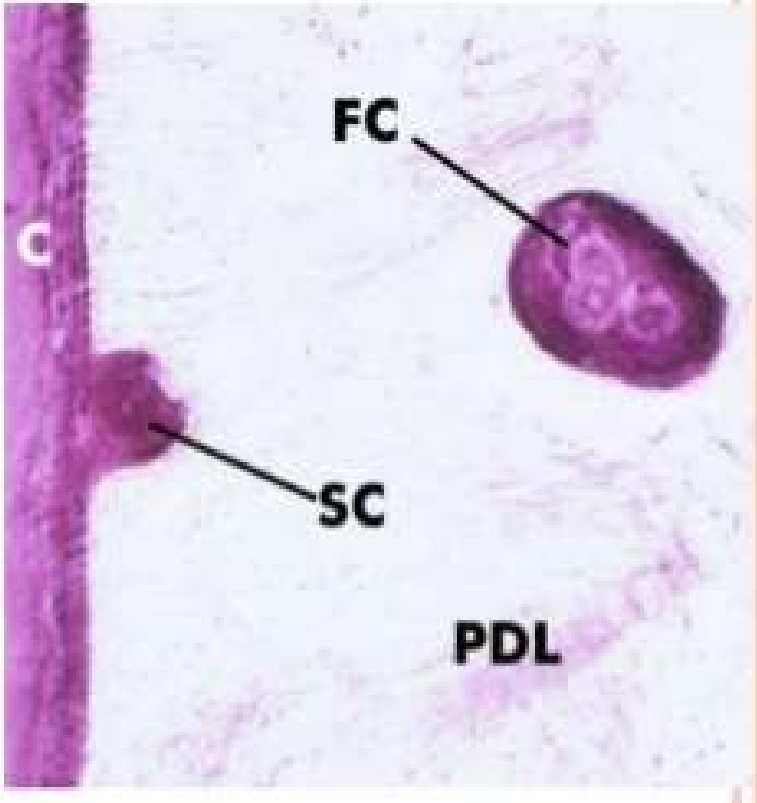

FC-free cementicle
SC-sessile cementicle

- **Permeability** : The permeability of cementum decreases gradually by age.

  The permeability from the periodontal side is lost except in the most recently formed layer of cementum, while that from the dentine side remains only in the apical region.

- **Cementum Resorption and Repair**: Cementum resorption can occur after trauma or excessive occlusal forces .

  After resorption ceases, the damage is usually repaired.

  If the repair establishes the former outline of the root surface it is called *anatomic repair*. However if only a thin layer of cementum is deposited and the root outline is not constructed it is called *functional repair*.

Thank tooth...